



# Askina® Calgitrol®

## CASE STUDIES



# INTRODUCTION

Since the launch of Askina® Calgitrol® Ag, Askina® Calgitrol® THIN and recently Askina® Calgitrol® Paste, we have received reports of treatment successes. We would like to share these with you today in the form of a short photo storyboard.

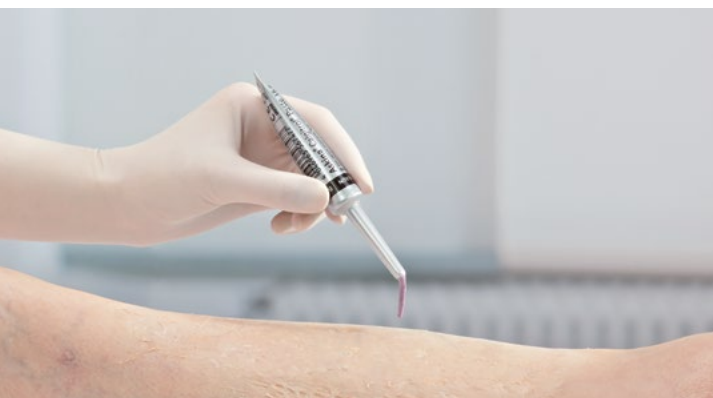
The prevention and treatment of wound infection is of the utmost importance in order to remove barriers to healing. Wound bed preparation and infection prevention are a prerequisite but treatment of local infection is essential for the healing process.

We would like to take this opportunity to thank all the doctors, nursing staff and B.Braun employees for forwarding the material and helping us put this picture book together.

**B. Braun Medical**

Center of Excellence Wound Management

## Askina® Calgitrol® Paste <sup>(1,2,3)</sup>



Highly conformable paste for close contact with the wound bed.

Provides for broad antimicrobial effectiveness

Long lasting antibacterial protection

Maintains a moist wound environment

Easy to remove by simply rinsing

Can be stored and used for 7 days if the lid / cap is replaced after use

Askina® Calgitrol® Paste is indicated for the management of partial to full thickness wounds, stage I -IV pressure ulcers, venous, arterial and neuropathic ulcers, second degree burns and donor sites.

Askina® Calgitrol® Paste is a highly conformable paste composed of the same ionic silver alginate matrix used in the Askina® Calgitrol® Ag flat dressings. The high conformability allows a closer contact between the active ionic silver alginate matrix and the wound bed, which is particularly **valuable in difficult to manage wounds such as tunnels and sinuses**, seen in patients with burns and neuropathic foot ulcers.




Askina® Calgitrol® Paste exists in different presentations

**Tubes** : 15g or 100g

**Jars** : 250g or 500g

## Askina® Calgitrol® Ag <sup>(1,3,4,5)</sup>



Broad antimicrobial effectiveness <sup>(1)</sup>

Immediate availability of silver ions <sup>(2)</sup>

Sustained controlled release to the wound bed during use of the dressing <sup>(2)</sup>

Tolerable and antimicrobially efficient <sup>(4)</sup>

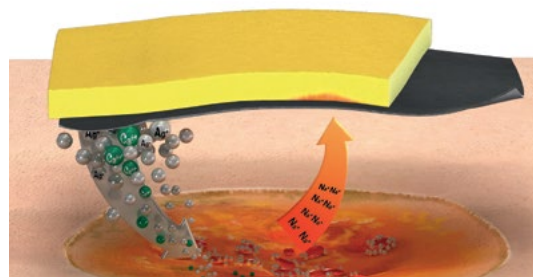
Easy to use & conformable <sup>(3)</sup>

No activation needed: ready to use

Askina® Calgitrol® Ag is indicated for the management of exuding partial full thickness wounds, stage I -IV pressure ulcers, venous ulcers, second degree burns and donor sites.

Askina® Calgitrol® Ag is a sterile dressing consisting of two layers:

- an absorbent polyurethane foam layer which provides for the absorption of wound exudate
- an ionic silver alginate matrix which provides for broad antimicrobial effectiveness and helps reduce the bacterial load



*In contact with wound exudate, the Calgitrol® ionic silver alginate matrix forms a soft gel allowing the liberation of silver ions.*

Dressings size available (10 Pieces / Pack):  
10 cm x10 cm, 15 cm x15 cm , 20 cm x 20 cm.

(1) Instruction for use: Askinal® Calgitrol I® Ag, Askina I® Calgitrol I® THIN, Askinal® Calgitrol I® Paste

(2) Opananon S, Magnette A, Meuleniére F, Harding K. Askina® Calgitrol® Made Easy. Wounds International 2012; 3(1). Available from [http:// www.woundsinternational.com](http://www.woundsinternational.com)

(3) Wounds International. Using Askina® Calgitrol® Paste for the treatment of diabetic foot infection: case studies. London: Wounds International 2013. Available for free download from: [www.woundsinternational.com](http://www.woundsinternational.com)

(4) Trial C, Darbas H, Lavigne J-P, Sotto A, Simoneau G, Tillet Y, et al. Assessment of the antimicrobial effectiveness of a new silver alginate wound dressing: a RCT. J Wound Care. 2010 Jan;19(1):20-6.

(5) Ricci E, Pittarello M, Cassino R. Askina Calgitrol® Ag: clinical use of an advanced ionic silver dressing. Acta Vulnologia. 2007;5(3):105-11.

(6) Opananon S, Muangman P, Namviriyachote N. Clinical effectiveness of alginate silver dressing in outpatient management of partial-thickness burns. Int Wound J. 2010 Dec;7(6):467-71

## Askina® Calgitrol® THIN <sup>(1)</sup>



Broad antimicrobial effectiveness <sup>(1)</sup>

Immediate availability of silver ions <sup>(2)</sup>

Sustained controlled release to the wound bed during use of the dressing <sup>(2)</sup>

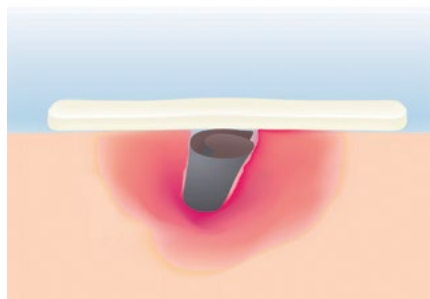
Tolerable and antimicrobially efficient <sup>(4)</sup>

Easy to use & conformable <sup>(3)</sup>

No activation needed: ready to use

Askina® Calgitrol® THIN is indicated for the management of partial to full thickness wounds : Stage I-IV pressure ulcers, venous ulcers, second degree burns and donor sites.

Askina® Calgitrol® THIN is a thin layer of ionic silver alginate matrix. Soft and conformable, it is well adapted for deep and difficult-to-dress wounds. It can be used with an absorptive secondary dressing, like Askina® Foam.



*Askina Calgitrol THIN is also suitable for cavity wounds.*

Dressings size available:

**10 Pieces / Pack:** 5 cm x 5 cm, 10 cm x 10 cm, 10 cm x 20 cm ,  
20 cm x 20 cm

**3 Pieces / Pack:** 20 cm x 40 cm, 30 cm x 30 cm , 40 cm x 40 cm

# CONTENT

## Askina® Calgitrol® Case Studies by wound type

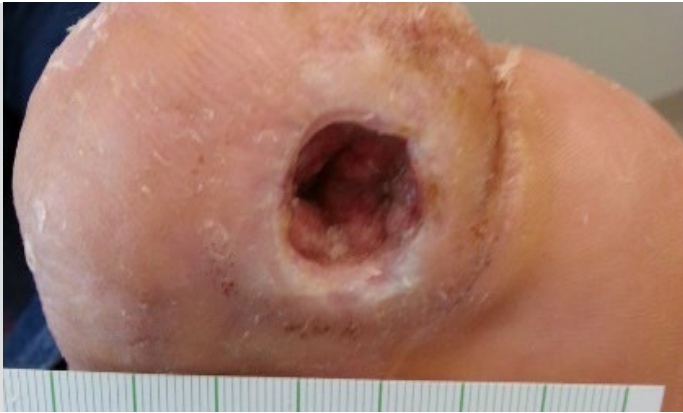
8-13	DIABETIC FOOT ULCERS
14-19	LEG ULCERS
20-25	PRESSURE ULCERS
26-31	BURNS
32-37	ACUTE WOUNDS

# DIABETIC FOOT ULCERS

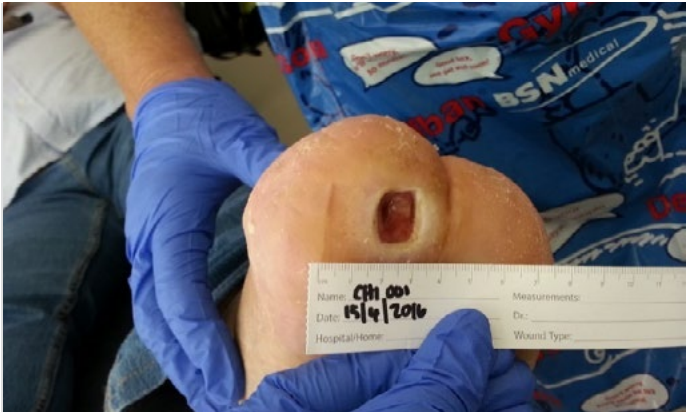## ASKINA® CALGITROL® PASTE

Responsible practitioner	Liezl Naude, RN
Centre	South Africa
Gender, age (years)	Male, 62 years
Past medical history	<ul style="list-style-type: none"><li>• Diabetes Type II (insulin-dependent)</li><li>• Severe neuropathy with history of previous amputations</li><li>• Chronic diabetes foot ulceration for the last four years</li></ul>
Wound diagnosis	<ul style="list-style-type: none"><li>• Abscess drained by an orthopaedic surgeon in January</li><li>• Plantar wound on the left foot</li></ul>
Wound profile	<ul style="list-style-type: none"><li>• Wound size: L=62 mm, W=50 mm, D=12 mm,</li><li>• 50 % granulation, 50 % epithelial tissue</li><li>• Clinical signs of localised infection</li><li>• High levels of exudate and maceration of the surrounding callous</li></ul>
Previous wound management	Negative Wound Pressure Therapy (NWPT) for two weeks then removal by the patient (mid March)
Reason(s) for switch to Askina® Calgitrol® Paste	To treat the local infection and manage exudate
Treatment regimen	<ul style="list-style-type: none"><li>• Prontosan® Gel used to soak the wound during 15/20 minutes, then wound was cleaned with saline</li><li>• Application of Askina® Calgitrol® Paste (for four weeks)</li><li>• Secondary dressings depending on the exudate level, such as non adhesive foam</li><li>• Dressings changed 2 or 3 times per week</li></ul>
Other treatment(s) used	Offloading
Clinical outcomes	<ul style="list-style-type: none"><li>• Wound improvement, less maceration one week after treatment</li><li>• By Week 2, wound size reduction, cleaned wound bed with 100 % granulation tissue</li><li>• By Week 4, eradication of all signs of infection, treatment with Askina® Calgitrol® discontinued</li></ul>
Treatment benefits	Askina® Calgitrol® paste shows: <ul style="list-style-type: none"><li>- Improvement of the wound healing process</li><li>- Decrease in pain and improvement in quality of life</li><li>- The paste is easy to apply and remove</li></ul>
Conclusion	Askina® Calgitrol® Paste permitted eradication of the local infection in this patient with high risk of amputation

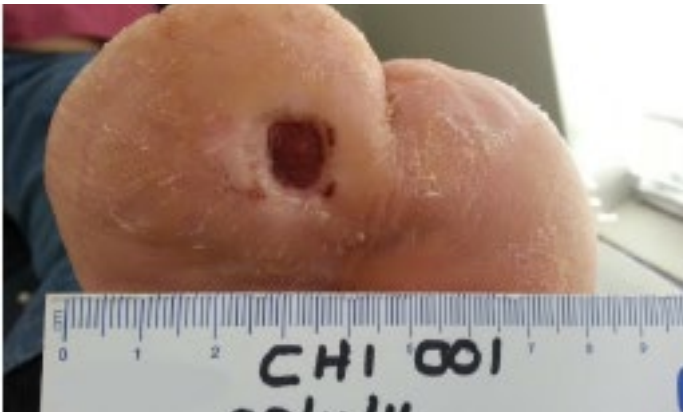



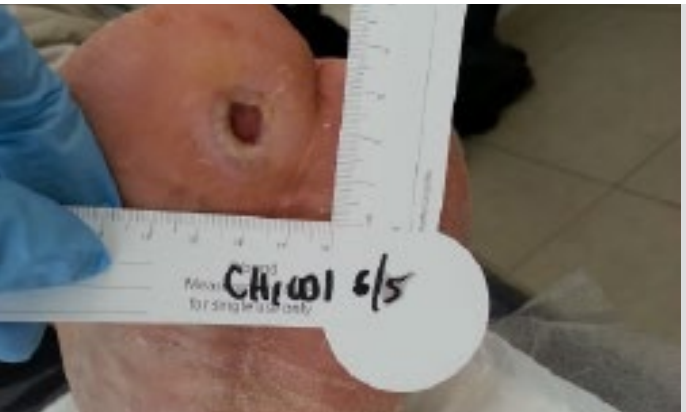Day 1



Week 2



Week 4

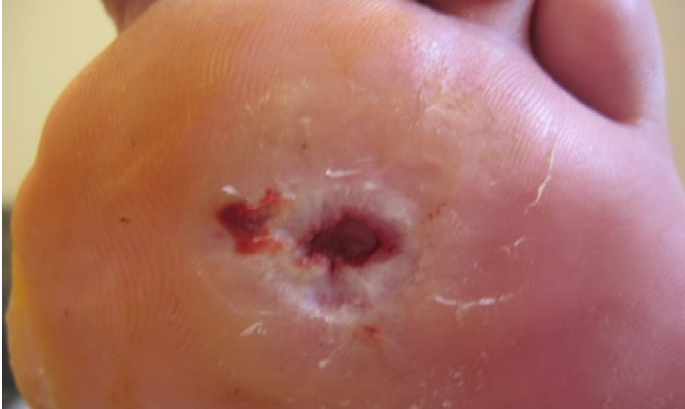

Week 5

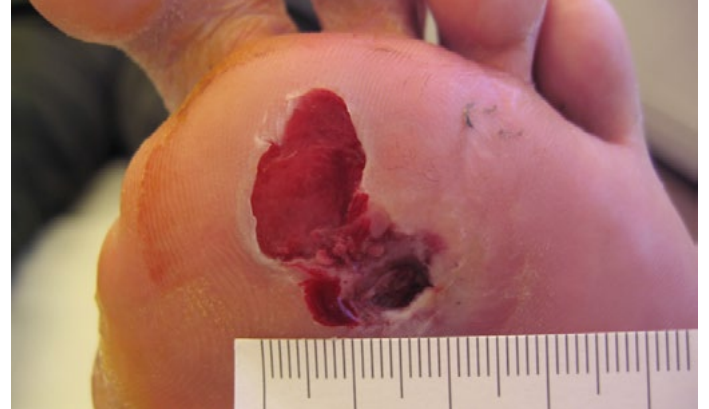# DIABETIC FOOT ULCERS

## ASKINA® CALGITROL® PASTE

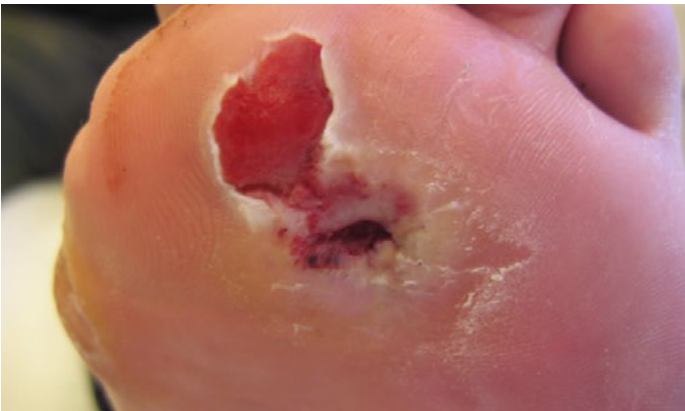Responsible practitioner	Anne Kataja, Foot therapist
Centre	Diabetes Clinic, Tampere, Finland
Gender, age (years)	Male, 72 years
Past medical history	<ul style="list-style-type: none"><li>• Patient with Type II diabetes</li><li>• Diabetic polyneuropathy and angiopathy in both lower limbs</li><li>• As a result both of his feet were numb</li><li>• Previous wounds treated with growth factors</li><li>• Left foot was revascularised</li></ul>
Wound diagnosis	Recurrent ulceration on the ball of left foot
Wound profile	<ul style="list-style-type: none"><li>• Wound size: L=9 mm, W=5 mm, D=3 mm,</li><li>• No slough, but thick callous surrounded wound</li><li>• Moderate exudate</li><li>• No signs of infection</li></ul>
Previous wound management	<ul style="list-style-type: none"><li>• Wound care was initiated with a gelling dressing</li><li>• Use of offloading with a felt and footwear to accommodate pressure</li><li>• Wound size reduction (L=5 mm, D=3 mm, W=3 mm) a month later</li><li>• Cleaned wound bed.</li><li>• Low level of exudates but callus surrounding the wound.</li><li>• Local wound care was changed to resin salve</li></ul>
Reason(s) for switch to Askina® Calgitrol® Paste	<ul style="list-style-type: none"><li>• Short-term use of normal shoes causes the wound to enlarge: L=7 mm, D=5 mm, W=5 mm</li><li>• A haematoma developed next to the wound, which had burst with leakage</li><li>• Ball of left foot slightly warmer than right foot</li></ul>
Treatment regimen	Askina® Calgitrol® Paste
Other treatment(s) used	-
Clinical outcomes	<ul style="list-style-type: none"><li>• After 24h, significant improvement of the wound bed</li><li>• By Day 11, reduction of the wound size L=2 mm, W=1 mm, D=2 mm</li><li>• There was good epithelialization</li><li>• Low level of exudates, no maceration</li><li>• Wound completely healed after 4 weeks of treatment</li></ul>
Treatment benefits	Fast wound healing of the diabetic foot ulcer in this patient with recurrent ulcers and history of constant ulceration
Conclusion	The use of Askina® Calgitrol® Paste in this patient resulted in complete healing of his chronic diabetic foot ulcer



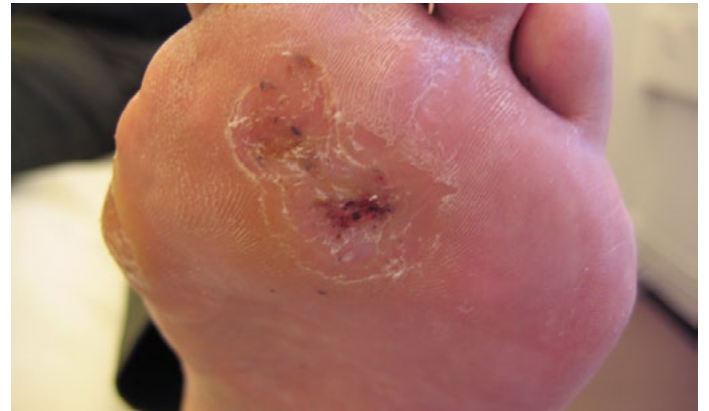Wound prior inclusion



Day 0 – Application of Askina® Calgitrol® Paste



Day 2 – Wound at 24 hours following application of Askina® Calgitrol® Paste

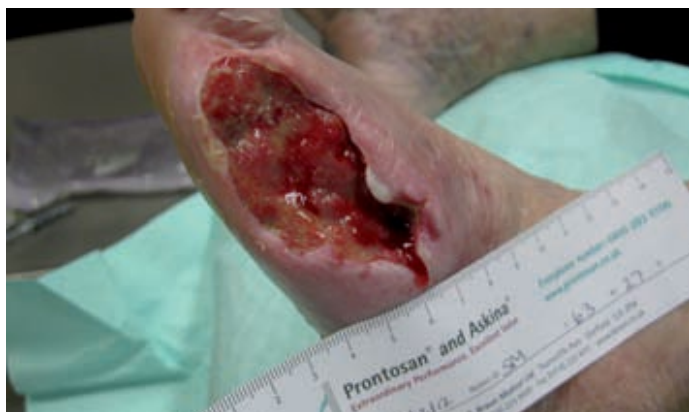

Day 11 – Wound healing in process

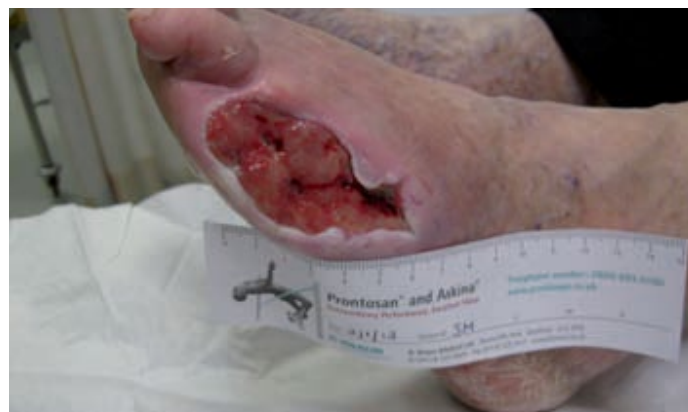# DIABETIC FOOT ULCERS

## ASKINA® CALGITROL® PASTE

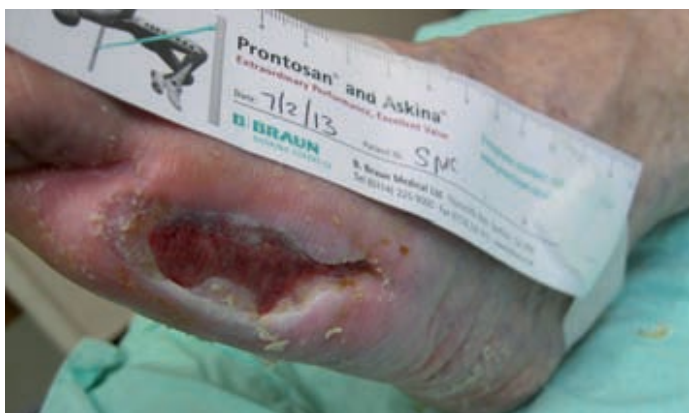Responsible practitioner	Samantha Haycocks, Dr Paul Chadwick
Centre	Podiatry department, Salford Royal Hospital, UK
Gender, age (years)	Female, 69 years
Past medical history	<ul style="list-style-type: none"><li>• Diabetes Type II (insulin-dependent)</li><li>• Peripheral arterial disease</li></ul>
Wound diagnosis	<ul style="list-style-type: none"><li>• Osteomyelitis</li><li>• Amputation of left 5th toe and distal third of metatarsal</li></ul>
Wound profile	<ul style="list-style-type: none"><li>• Wound size: L=63 mm, W=27 mm</li><li>• Surface area : 1734 mm<sup>2</sup></li><li>• Clinical signs of localised infection</li><li>• Granulation tissue and slough</li><li>• High levels of exudate</li></ul>
Previous wound management	-
Reason(s) for switch to Askina® Calgitrol® Paste	To reduce the signs and symptoms of infection
Treatment regimen	Application of Askina® Calgitrol® Paste during four weeks
Other treatment(s) used	Offloading
Clinical outcomes	<ul style="list-style-type: none"><li>• By Week 1, good evolution</li><li>• By Week 6, very good wound improvement, wound size reduction ( L=30 mm, W=15 mm) with area decrease of 45 %</li></ul>
Treatment benefits	<ul style="list-style-type: none"><li>• Askina®Calgitrol® paste shows:<ul style="list-style-type: none"><li>- Improvement of the wound healing process</li><li>- Ideal use on difficult to manage wound shapes, and tunnels</li><li>- Ease of application</li></ul></li></ul>
Conclusion	Askina® Calgitrol® Paste permitted to reduce the local infection in this patient with amputation



Wound at inclusion



Wound one week after



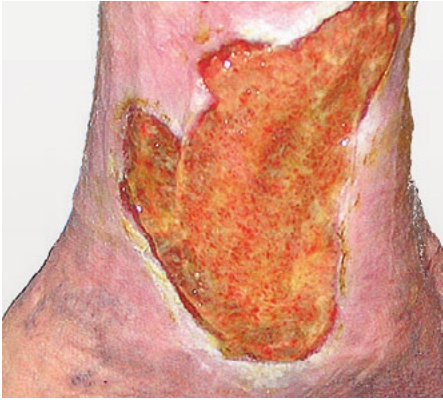Wound 6 weeks after

# LEG ULCERS

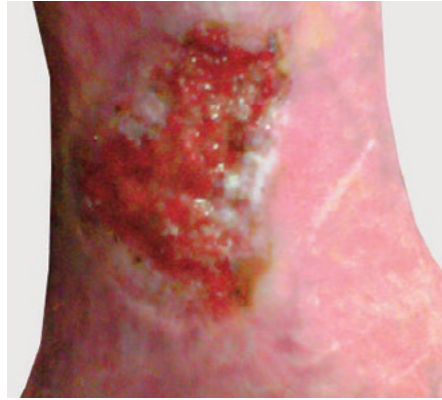
ASKINA® CALGITROL® AG

Responsible practitioner	Simon Barrett
Centre	Humber NHS Foundation Trust, East Yorkshire, United Kingdom
Gender, age (years)	Male, 74 years
Past medical history	<ul style="list-style-type: none"><li>• Rhumatoid arthritis</li><li>• Recent malignant lesions to scalp</li><li>• Post traumatic wound to left inner ankle at age 40</li></ul>
Wound diagnosis	Ulcer, which failed to heal during the previous 34 years despite most up to date intervention
Wound profile	<ul style="list-style-type: none"><li>• Wound size: L=12 cm, W=8 cm</li><li>• Superficial depth, 100 % liver red, critically colonized, high volume of exudate, low viscosity</li></ul>
Previous wound management	<ul style="list-style-type: none"><li>• Skin grafting, bed rest and elevation, compression therapy and electrical stimulation</li><li>• Use of several antimicrobial dressings e.g. iodine, silver and Prontosan®</li><li>• Dressings changed three times per week to manage exudate and due to maceration</li></ul>
Reason(s) for switch to Askina® Calgitrol® Ag	The skin breakdown did not respond to any conventional or advanced therapies for a period of approximately two years
Treatment regimen	Two dressings per week
Other treatment(s) used	Multi layer compression therapy
Clinical outcomes	<ul style="list-style-type: none"><li>• Significant wound size reduction to L=3 cm, W=2 cm</li><li>• Decreased level of exudate</li><li>• Wound bed is 100 % healthy red, very superficial wound</li></ul>
Treatment benefits	<ul style="list-style-type: none"><li>• Very good exudate management, no further maceration dressing change twice a week</li><li>• The dressing is conformable to apply</li><li>• Dressings are comfortable for the patient</li></ul>
Conclusion	<ul style="list-style-type: none"><li>• Having lived with it for 34 years, the leg ulcer has now healed, which has dramatically changed the patient's life</li><li>• Askina® Calgitrol® Ag is cost effective: reduction of the dressing changes (from 3 to 2 per week) resulting in reduced nursing time</li></ul>

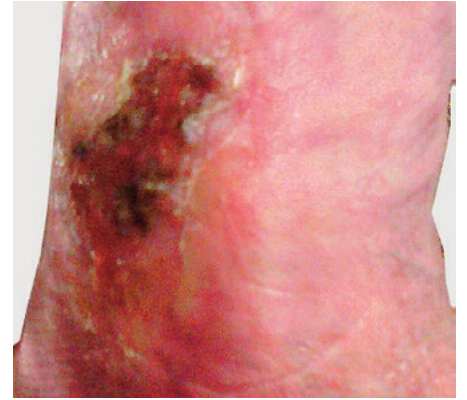




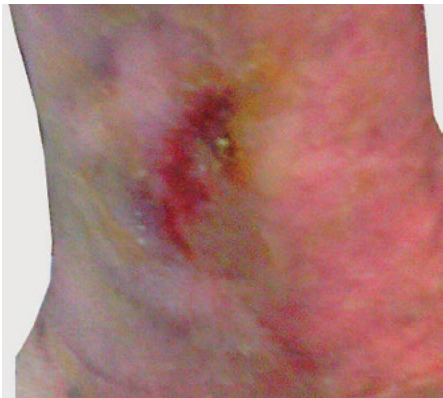
Week 1



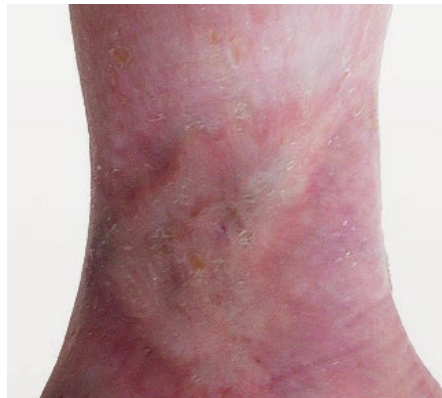Week 4



Week 8



Week 12



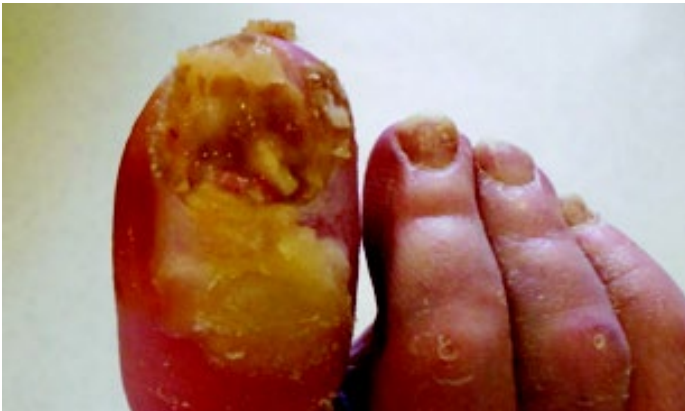Final result

# LEG ULCERS

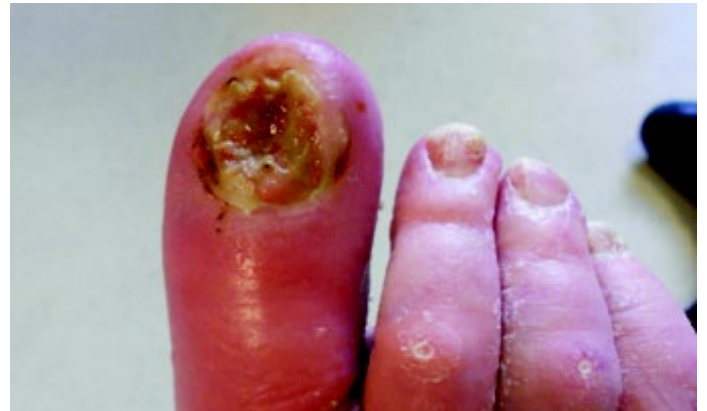## ASKINA® CALGITROL® PASTE

Responsible practitioner	Katharine Speak, Clinical Lead Podiatrist
Centre	Centre For Diabetes and Endocrinology, York Hospital, York, United Kingdom
Gender, age (years)	Female, 93 years
Past medical history	<ul style="list-style-type: none"><li>Peripheral arterial disease: Superior femoral angioplasty deemed successful, resulting in in-line flow</li><li>Cardiac disease (heart failure, atrial fibrillation..)</li><li>No diabetes</li><li>The patient was living independently with help from the family and her level of self-care was good</li></ul>
Wound diagnosis	<ul style="list-style-type: none"><li>Ischaemic great toe with subungual ulceration</li><li>Symptoms started approximately one month earlier</li></ul>
Wound profile	<ul style="list-style-type: none"><li>Wound was covered 100 % in slough, was difficult to sharp debride</li><li>Wound was malodorous</li><li>Erythema on the peri-wound skin</li><li>Nail had avulsed</li></ul>
Previous wound management	<ul style="list-style-type: none"><li>Iodine dressing causing irritation making it uncomfortable especially at night</li><li>Previous dressing applied too tightly causing a secondary ulcer at the base of the toe</li></ul>
Reason(s) for switch to Askina® Calgitrol® Paste	Irritation and traumatism with iodine dressing
Treatment regimen	<ul style="list-style-type: none"><li>Cleansing with saline solution</li><li>Application of Askina® Calgitrol® Paste</li><li>Dressing changes done every three days at home</li><li>Askina® Calgitrol® Paste was applied for a further week after which it was stopped</li><li>A silicon foam dressing was applied thereafter</li></ul>
Other treatment(s) used	-
Clinical outcomes	<ul style="list-style-type: none"><li>Marked improvement of the toe after one week</li><li>The slough had lifted with granulation tissue showing in small areas of the wound</li><li>Two weeks following treatment the nail bed was clean and granulating well</li></ul>
Treatment benefits	<ul style="list-style-type: none"><li>Some erythema was still evident but the patient was really pleased, reporting greater comfort and undisturbed sleep</li><li>Due to the antimicrobial effectiveness of Askina® Calgitrol® Paste no antibiotic therapy was required resulting in lower treatment costs</li></ul>
Conclusion	Askina® Calgitrol® Paste treatment resulted in rapid healing of the leg ulcer, improved quality of life for the patient and lower treatment costs

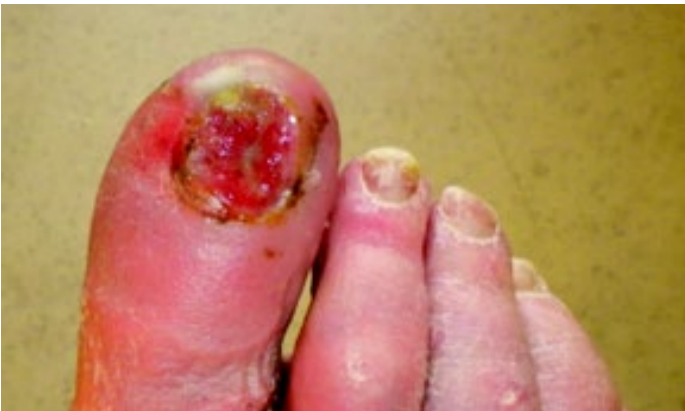



Day 1 – Pre-treatment



Week 1 – Following treatment with Askina® Calgitrol® Paste

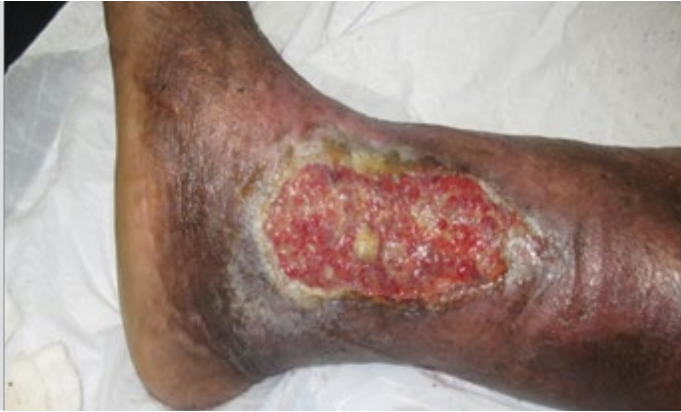

Week 2 – Clean nail bed and wound granulating

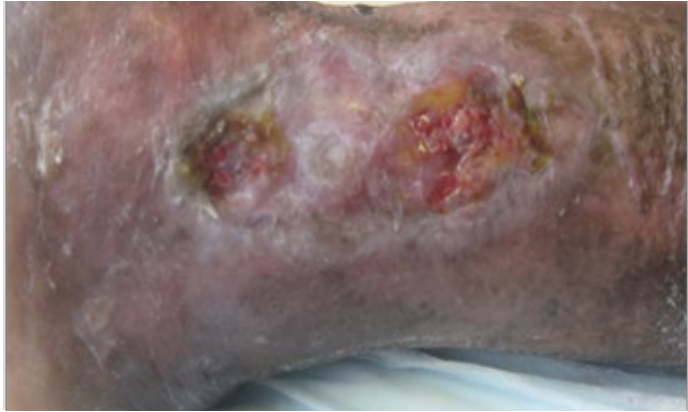# LEG ULCERS

## ASKINA® CALGITROL® PASTE

Responsible practitioner	Mazizi Njokweni, Podiatry Dpt
Centre	Leratong Hospital, Gauteng, South Africa
Gender, age (years)	Female, 54 years old
Past medical history	<ul style="list-style-type: none"><li>• Hypertension</li><li>• Recurrent chronic Venous Leg Ulcer present for 18 years</li></ul>
Wound diagnosis	Recurrence of venous leg ulcers present for 18 years
Wound profile	<ul style="list-style-type: none"><li>• The methodology of the case study was a random selection of subjects with chronic venous leg ulcers that have been present for more than 1 year.</li><li>• The period of the trial was 8 weeks with chronic venous leg ulcers consultations once a week .</li><li>• At 1<sup>st</sup> consultation chronic leg ulcer presented with raised and inflamed wound edges, macerated peri-wound areas, fibrin with slough, moderate to high exuding wounds and pain grade above 3</li></ul>
Previous wound management	-
Reason(s) for switch to Askina® Calgitrol® Paste	<ul style="list-style-type: none"><li>• Bacterial infections , if not treated properly, can lead to a delay in wound healing and induce severe systemic complications</li><li>• The primery objective was to examine the use of Prontosan® solution to control the bioburden of the wound bed and askina calgitrol paste to properly treat the Bacterial infection</li></ul>
Treatment regimen	Askina® Calgitrol® Paste dressing was changed once a week on a period of 8 weeks
Other treatment(s) used	-
Clinical outcomes	<ul style="list-style-type: none"><li>• At last consultation chronic wound ulcer showed significant improvement.</li><li>• Reduction of the level of exudate</li><li>• Significant pain reduction</li><li>• Promotion of granulation tissue</li></ul>
Treatment benefits	<ul style="list-style-type: none"><li>• Real improvement in stagnant ulceration</li><li>• Accelerated closure of the ulcerreduction in pain</li></ul>
Conclusion	The combination of Prontosan® solution and Askina® Calgitrol® Paste in chronic venous leg ulcer is appropriate and relevant to reduce local infection and promote tissue viability when other treatments had failed.



Day 1 : wound at inclusion

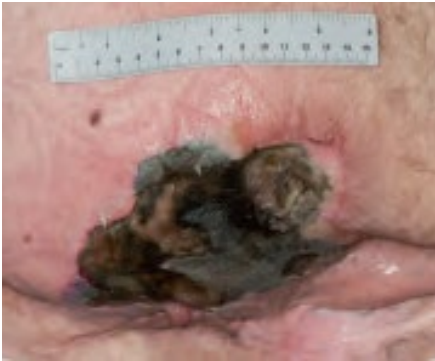

Week 8 : good wound improvement

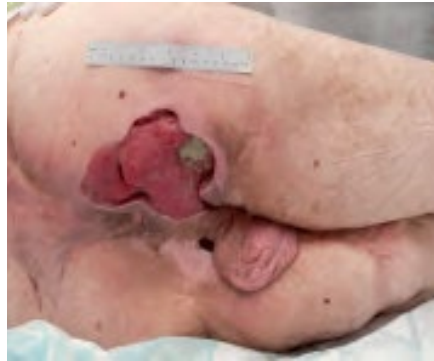# PRESSURE ULCERS

## ASKINA® CALGITROL® AG

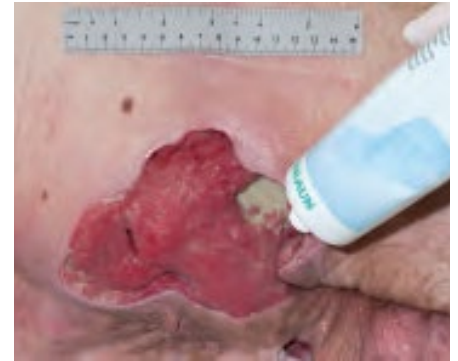
Responsible practitioner	Lindsey Bullough, Tissue Viability Nurse
Centre	Wrightington, Wigan and Leigh NHS Foundation Trust, United Kingdom
Gender, age (years)	Male, 49 years
Past medical history	<ul style="list-style-type: none"><li>The patient has a history of spina bifida</li><li>He is immobile and confined to a wheelchair but is independent with activities of daily living</li></ul>
Wound diagnosis	Category 4 pressure ulcer -> admission to the hospital
Wound profile	<ul style="list-style-type: none"><li>Size: L=15 cm, W=20 cm</li><li>Necrotic tissue covering the whole wound</li><li>Infected wound: A swab identified MRSA</li></ul>
Previous wound management	<ul style="list-style-type: none"><li>The necrosis was sharply debrided</li><li>After sharp debridement, Prontosan® irrigation solution and gel were used to remove any biofilm and complete the debridement process</li></ul>
Reason(s) for switch to Askina® Calgitrol® Ag	Provide an active concentration of silver ions on wound bed to reduce local infection, to support the debridement process and control the exudates
Treatment regimen	<p><b>Step 1:</b></p> <ul style="list-style-type: none"><li>A layer of gauze soaked in Prontosan® irrigation solution was placed onto the necrotic tissue for 15 minutes prior to applying Prontosan® gel</li><li>Askina® Calgitrol® Ag was applied with an adhesive film to secure in place</li><li>The dressing was replaced every alternate day until the necrosis was softened, revealing soft yellow slough</li><li>Debridement of the wound was then carried out</li></ul> <p><b>Step 2:</b></p> <ul style="list-style-type: none"><li>After necrosis debridement, dressing changes were undertaken on a daily basis to manage the high level of exudate</li></ul>
Other treatment(s) used	-
Clinical outcomes	<p><b>Day 20</b></p> <ul style="list-style-type: none"><li>Wound size reduction (L=11 cm, W=15 cm)</li><li>Decrease of slough by 90 %</li><li>Reduction of dressing changes to twice weekly due to a decrease of the exudate</li></ul> <p><b>Day 26</b></p> <ul style="list-style-type: none"><li>Good progression of the wound healing with a wound size reduction (L=10.5 cm, W=14.75 cm)</li><li>Minimal slough</li></ul>
Treatment benefits	Dressing changes decreased with the level of exudates from daily to twice weekly saving on nursing time and reducing discomfort for the patient
Conclusion	<p>Askina® Calgitrol® Ag</p> <ul style="list-style-type: none"><li>Contributed to the rapid clearing of infection leading to wound progression in this stage 4 pressure ulcer</li><li>Controlled exudate from which no maceration was seen to the surrounding skin</li></ul>



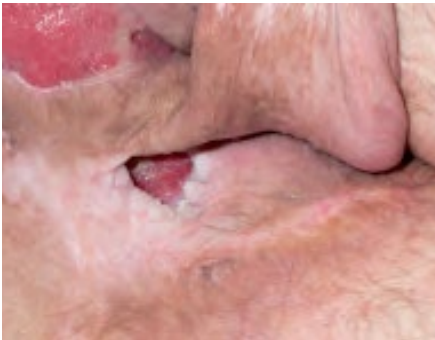Day 1



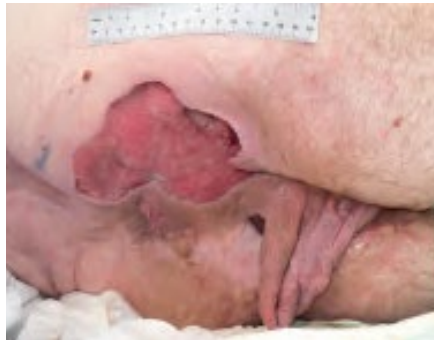Day 20



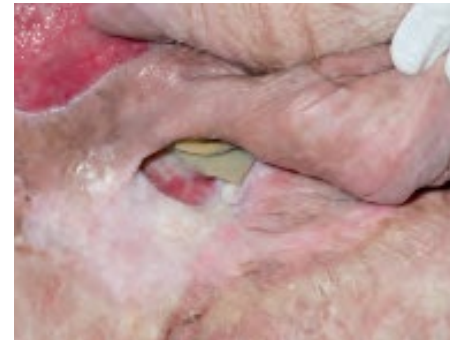Day 20



Day 20



Day 26

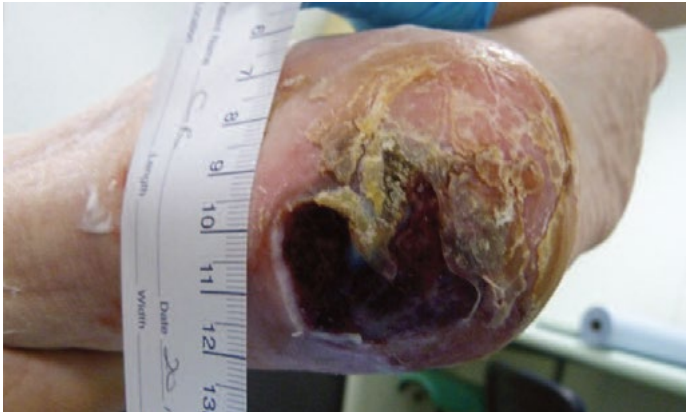

Day 26

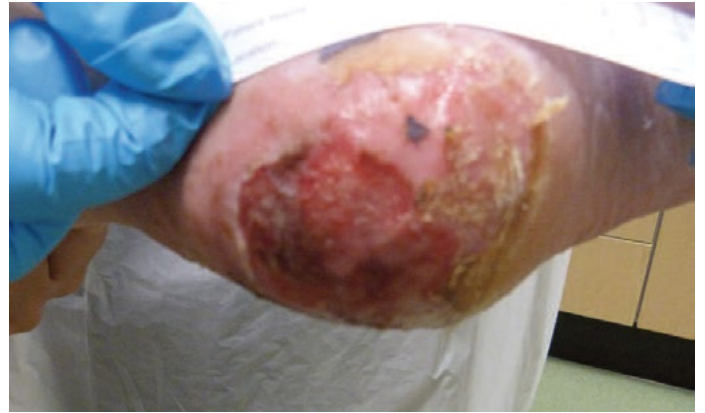# PRESSURE ULCERS

## ASKINA® CALGITROL® AG

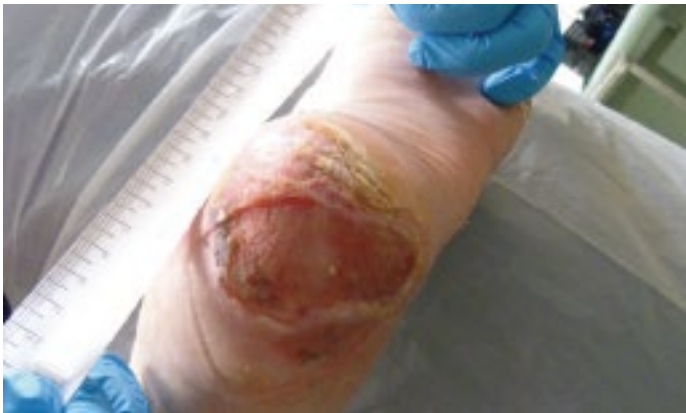Responsible practitioner	Sue Johnson, Lead Nurse
Centre	Wound Care, Doncaster and Bassetlaw Hospitals NHS Foundation Trust, Doncaster, United Kingdom
Gender, age (years)	Male, 54 years
Past medical history	<ul style="list-style-type: none"><li>• Paraplegic following accident</li><li>• Recurring right heel pressure ulcers over a six year period</li></ul>
Wound diagnosis	Presented with self-inflicted traumatic wounds to left leg
Wound profile	<ul style="list-style-type: none"><li>• The wound was clinically critically colonized with surrounding erythema, odour and increased exudate</li><li>• 100 % of necrotic tissue on the wound bed</li></ul>
Previous wound management	-
Reason(s) for switch to Askina® Calgitrol® Ag	The pressure ulcer was critically colonized and it's recognized that ionic silver is safe and effective in complex wounds
Treatment regimen	<ul style="list-style-type: none"><li>• Askina® Calgitrol® Ag was used in conjunction with Viscopaste sofban and a Klite bandage</li><li>• The dressing was changed weekly</li></ul>
Other treatment(s) used	<ul style="list-style-type: none"><li>• Viscopaste sofban</li><li>• Klite pressure bandage toe to knee to reduce oedema</li></ul>
Clinical outcomes	<ul style="list-style-type: none"><li>• The necrotic tissue was largely removed within one week of initiating treatment with Askina® Calgitrol® Ag</li><li>• Important decrease of the exudate level compared to pre-treatment levels</li><li>• Infection resolved in two weeks</li><li>• Important size reduction within two weeks</li></ul>
Treatment benefits	Askina® Calgitrol® Ag was clinically effective and rapidly reduced necrosis, infection and exudate in this patient with complex wounds
Conclusion	Askina® Calgitrol® Ag is a cost-effective alternative to other silver products and also reduces secondary dressing costs without increasing nursing time



Day 0



Week 2



Week 3

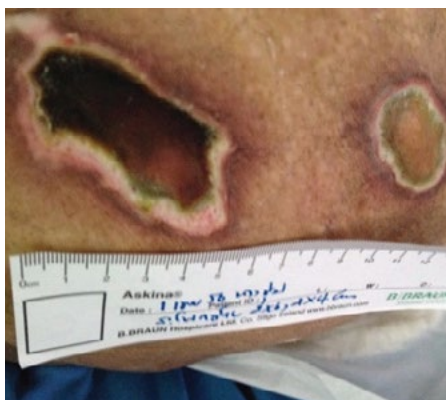

# PRESSURE ULCERS

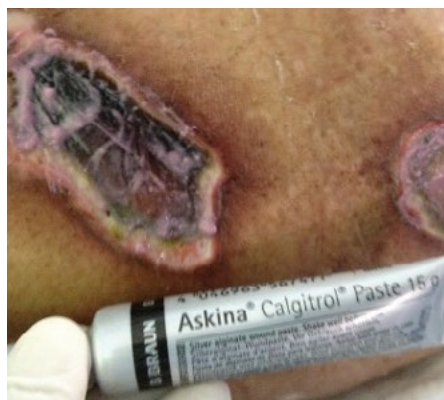## ASKINA® CALGITROL® PASTE

Responsible practitioner	Ponghatai Pumraya, MSN, RN
Centre	Wound Care Clinic, Nopparat Rajathanee Hospital, Bangkok, Thailand
Gender, age (years)	Female, 71 years
Past medical history	<ul style="list-style-type: none"><li>• Cerebrovascular accident (CVA)</li><li>• Sepsis</li><li>• Patient requires assistance with daily living</li></ul>
Wound diagnosis	Two unstageable pressure ulcers, left buttock
Wound profile	<ul style="list-style-type: none"><li>• Size: L=2.0 cm, W=6 cm and L=1 cm, W=3 cm</li><li>• The wound beds were covered with black and brown eschars and slough</li></ul>
Previous wound management	-
Reason(s) for switch to Askina® Calgitrol® Paste	Alternative treatment for an elderly patient who could not tolerate the removal of necrosis by surgical procedure
Treatment regimen	<ul style="list-style-type: none"><li>• Wound cleansing with saline solution</li><li>• Application of Askina® Calgitrol® Paste on the wound bed</li><li>• A foam dressing was used as the secondary dressing</li><li>• Dressing changes every 3-4 days until the dark necrosis was removed</li></ul>
Other treatment(s) used	-
Clinical outcomes	Marked wound bed improvement: The eschars from the two unstageable pressure ulcers were removed within 18 days after Askina® Calgitrol® Paste application
Treatment benefits	<ul style="list-style-type: none"><li>• The paste is comfortable to apply for the patient</li><li>• Both the patient and caregiver were pleased with the outcome of the treatment</li></ul>
Conclusion	<ul style="list-style-type: none"><li>• Askina® Calgitrol® Paste is an effective alternative to remove eschars in patients at risk from surgical debridement</li><li>• Askina® Calgitrol® Paste supports wound healing and is considered safe for the patient</li></ul>

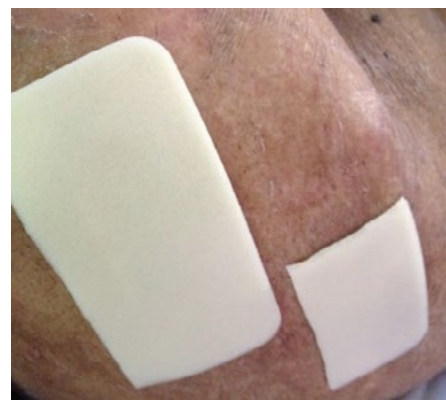



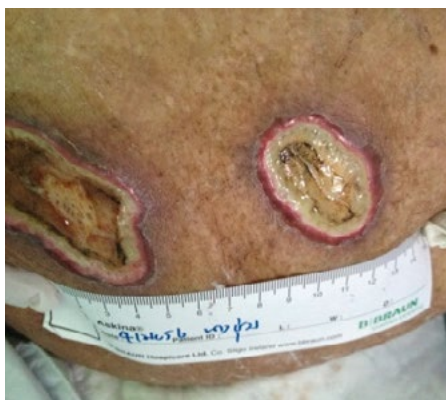Day 1 – At inclusion



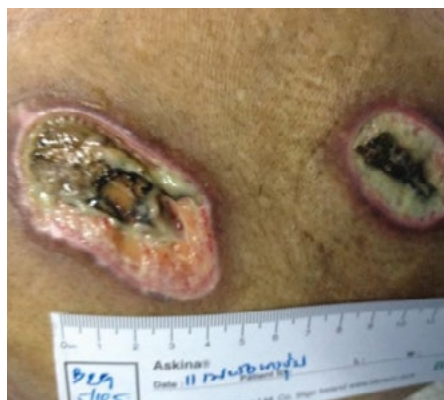Day 1 – Application of Askina® Calgitrol® Paste



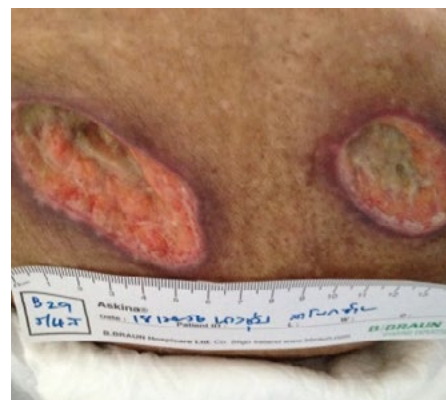Day 1 – Dressings in place on both wounds



Day 3 – Wound evolution



Day 10 – Wound evolution

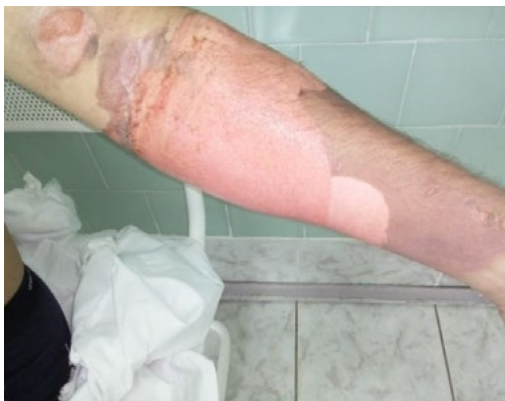

Day 18 – Wounds demonstrating removal of necrosis tissue

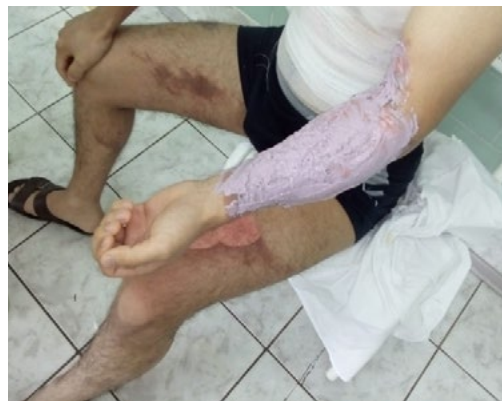# BURNS

## ASKINA® CALGITROL® PASTE

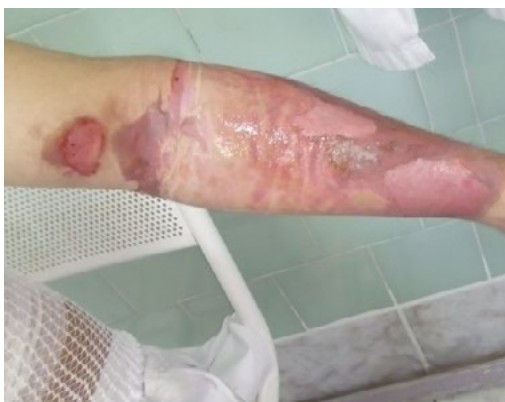Responsible practitioner	Evgeny Zinovyev, PR
Centre	Burns Unit, Leningrad Regional Hospital, St. Petersburg, Russia
Gender, age (years)	Male, 24 years
Past medical history	The patient was admitted to hospital as an emergency case three hours after injury
Wound diagnosis	Partial thickness flame burn
Wound profile	The burn affected 12 % of the total surface area of the trunk and extremities
Previous wound management	Not applicable
Reason(s) for switch to Askina® Calgitrol® Paste	Evaluation of a new dressing, Askina® Calgitrol® Paste
Treatment regimen	<ul style="list-style-type: none"><li>• Askina® Calgitrol® Paste alone was initially applied on a daily basis to the burns</li><li>• Dressing changes were based on an evaluation of the condition of the wound, adhesion of the dressing, level of suppuration, bleeding</li></ul>
Other treatment(s) used	-
Clinical outcomes	<ul style="list-style-type: none"><li>• Askina® Calgitrol® Paste dressing was 'rejected' on Day 6. The wound surface was covered with mucous exudate and fibrin, under which could be seen numerous areas of regional and focal epithelialisation</li><li>• Askina® Calgitrol® was re-applied, this time with a gauze bandage to hold it close to the skin surface for a further six days</li><li>• Complete wound epithelialisation on both the trunk and extremities after 12 days</li></ul>
Treatment benefits	<ul style="list-style-type: none"><li>• Askina® Calgitrol® Paste improved the treatment of dermal burns in this patient by reducing :<ul style="list-style-type: none"><li>- Time to wound healing</li><li>- Duration of individual stages of the wound healing process (reducing time of rejection of the burn eschar)</li><li>- Frequency of suppuration</li></ul></li></ul>
Conclusion	Askina® Calgitrol® Paste is very cost effective as it reduces both the time of wound healing and the overall cost of treatment



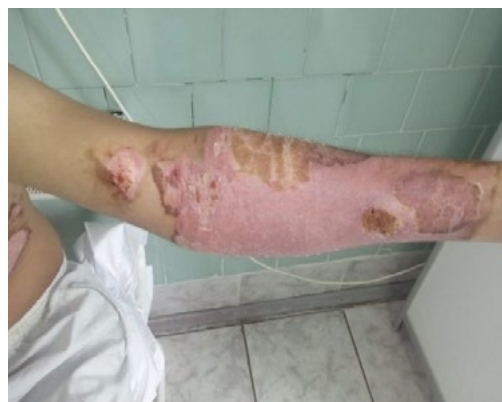Day 1 – Burn at inclusion



Day 1 – Application of Askina® Calgitrol® Paste



Day 6 – Good evolution

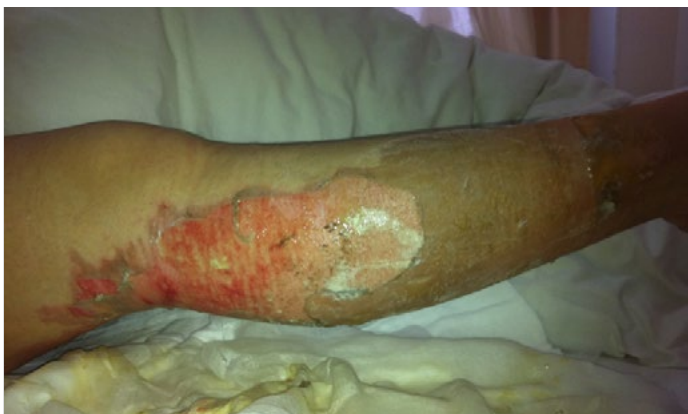

Day 12 – Complete epithelialisation

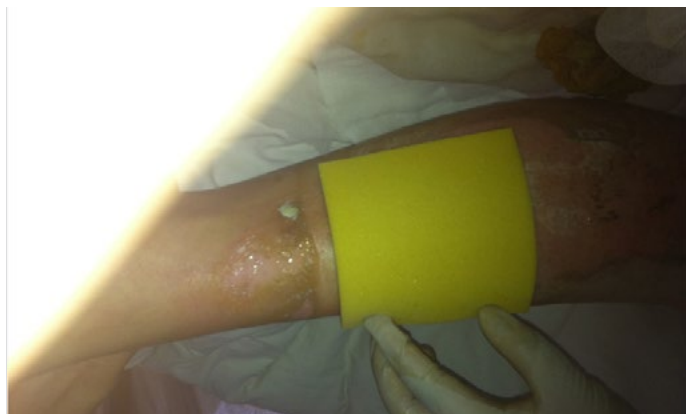# BURNS

ASKINA® CALGITROL® AG

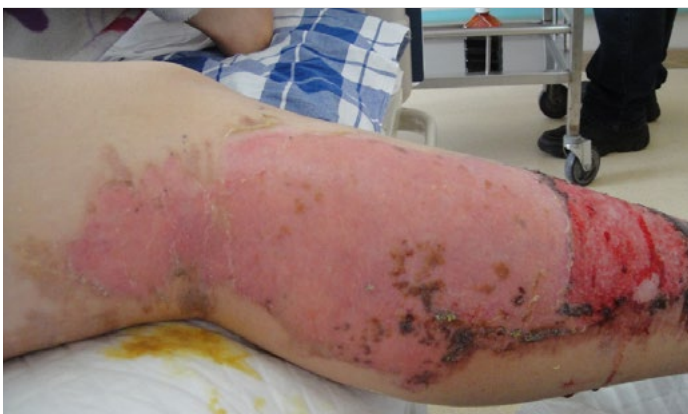Responsible practitioner	Jinghua Zang
Centre	Burn Unit, Heilongjiang Province Hospital, Harbin, China
Gender, age (years)	Female, 23 years
Past medical history	The patient suffered burns when a pot of boiling water spilt over her right leg
Wound diagnosis	Right leg dermal burns
Wound profile	Partial thickness burns involving 4 % of the body surface area
Previous wound management	1 % silver sulfadiazine (1 % AgSD) was used once (Day 1)
Reason(s) for switch to Askina® Calgitrol® Ag	Evaluation of a new dressing, Askina® Calgitrol® Ag
Treatment regimen	Application of Askina® Calgitrol® Ag on Day 2 post-injury
Other treatment(s) used	-
Clinical outcomes	<ul style="list-style-type: none"><li>• Partial epithelialisation by Day 12</li><li>• Partial wound healing on Day 16 -&gt; patient discharge</li></ul>
Treatment benefits	<ul style="list-style-type: none"><li>• Compared with 1% AgSD cream (traditional treatment), Askina® Calgitrol® Ag was:<ul style="list-style-type: none"><li>- Much easier to apply and remove, making it more comfortable for the patient</li><li>- Easier use for the nurse</li><li>- Left on the wound for up to seven days and therefore both the frequency of dressing changes and pain control medication was significantly reduced</li></ul></li></ul>
Conclusion	<ul style="list-style-type: none"><li>• Askina® Calgitrol® Ag dressing is a safe treatment for partial thickness burns as it exerts a highly antimicrobial effect and provides an optimal moisture-balanced healing environment.</li></ul>



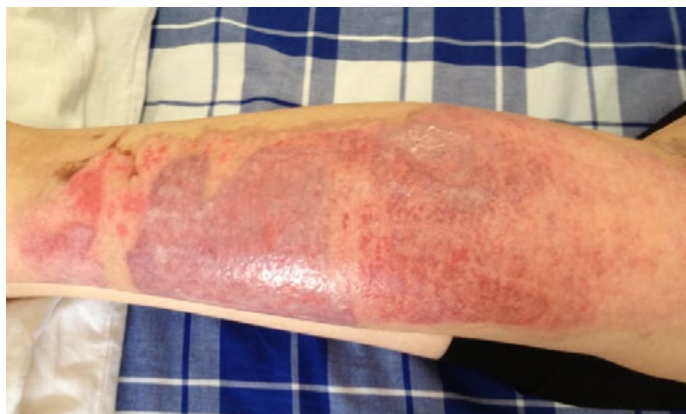Day 1 - Post-burn



Day 2 - Application of Askina® Calgitrol® Ag



Day 12 - Partial epithelialisation of the wound



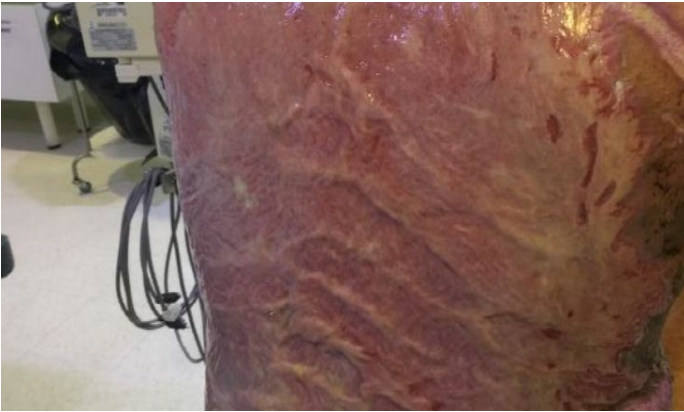Day 16 - Almost healed wound

# BURNS

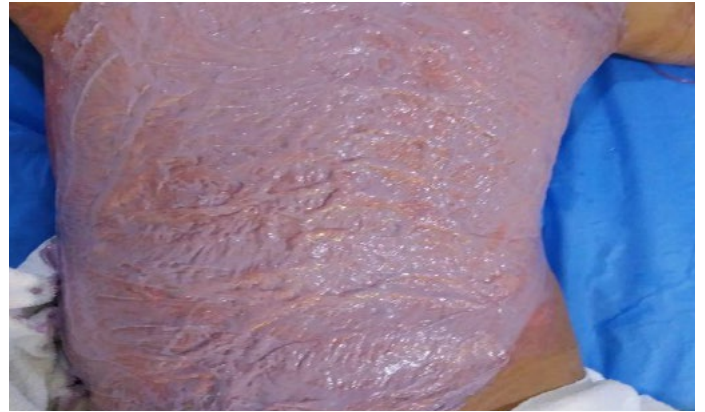## ASKINA® CALGITROL® PASTE

Responsible practitioner	Carlos Segovia and Magaly Yarza, Intensive care Nurses
Centre	Burn ICU Hospital Clinico Mutual de Seguridad, Santiago, Chile
Gender, age (years)	Male, 31 years
Past medical history	Deep partial thickness burn (hot water) occurred at age of 2. Back and Lower limbs are currently cover with a keloid
Wound diagnosis	Severe burns caused by fire from gaz explosion
Wound profile	<ul style="list-style-type: none"><li>• TBSA: 39 %</li><li>• Superficial Partial thickness Burn: Facial 6 %</li><li>• Superficial Partial thickness Burn : Cervical 1,5 %</li><li>• Superficial Partial thickness Burn: Back 18 %</li><li>• Superficial Partial thickness Burn : Upper limbs 13,5 %</li></ul>
Previous wound management	-
Reason(s) for use of Askina® Calgitrol® Paste	<ul style="list-style-type: none"><li>• Impossible to perform an early scarectomy due to medical record</li><li>• It was decided to prepare the wound bed for further dermoepidermal graft with Askina® Calgitrol® Paste</li></ul>
Treatment regimen	<ul style="list-style-type: none"><li>• Wound bed preparation with Prontosan® solution</li><li>• Application of Askina® Calgitrol® Paste (primary dressing)</li><li>• Secondary dressing with Gauze with petrolatum</li><li>• Traditional dressings on the top</li><li>• Treatment of 12 days in total with daily dressings changes</li></ul>
Other treatment(s) used	Hydrotherapy on daily basis
Clinical outcomes	<ul style="list-style-type: none"><li>• Askina® Calgitrol® Paste demonstrated to be an excellent alternative for wound bed preparation before grafts</li><li>• Successful dermoepidermal graft</li></ul>
Treatment benefits	<ul style="list-style-type: none"><li>• Excellent synergy between Prontosan® solution ( for biofilm and inflammatory parameters) and Askina® Calgitrol® Paste (for bacterial bioburden and exudates)</li><li>• Decreased antibiotics consumption</li><li>• Less pain</li></ul>
Conclusion	<ul style="list-style-type: none"><li>• Decreased nursing workload</li><li>• Early discharge of the patient from ICU</li><li>• Decreased total cost of patient treatment</li></ul>





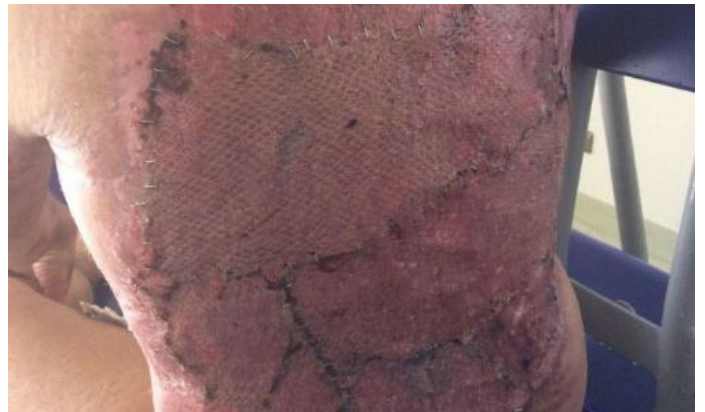1- Burn on the back



2- Application of Askina® Calgitrol® Paste



3- Sterile petrolatum gauze used as secondary dressing



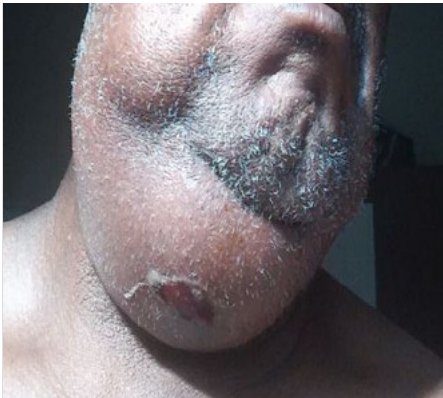4- Successful dermoepidermal graft

# ACUTE WOUNDS

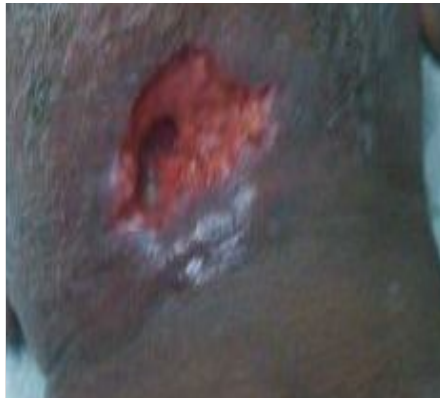## ASKINA® CALGITROL® PASTE

Responsible practitioner	Danielle Frassi Bastos
Centre	B Braun, Brazil
Gender, age (years)	Male, 68 years
Past medical history	-
Wound diagnosis	<ul style="list-style-type: none"><li>• Wisdom tooth extraction</li><li>• Application of dry ice after the procedure for one hour to reduce the swelling -&gt; created a burn to the neck</li></ul>
Wound profile	<ul style="list-style-type: none"><li>• Wound Size: L=5.5 cm, W=5.0 cm</li><li>• Purulent wound</li></ul>
Previous wound management	Not applicable
Reason(s) for switch to Askina® Calgitrol® Paste	Abscess wound with pus
Treatment regimen	<ul style="list-style-type: none"><li>• Cavity wound is cleaned with Prontosan® solution</li><li>• Application of Askina® Calgitrol® Paste in conjunction with a secondary gauze dressing</li><li>• Dressing changes every third day</li></ul>
Other treatment(s) used	Prontosan® solution for wound bed cleansing
Clinical outcomes	<ul style="list-style-type: none"><li>• Wound size reduction to L=5 cm, W=3 cm at Day 4</li><li>• Size reduction over time</li><li>• By Day 15 it measured L=1.5 cm, W=1.0 cm</li><li>• Complete wound healing at day 23</li></ul>
Treatment benefits	Very rapid wound healing for this large and cosmetically obvious wound
Conclusion	Use of Askina® Calgitrol® Paste in the early stages post-injury resulted in prevention of infection together with rapid and complete healing of an acute chemical burn

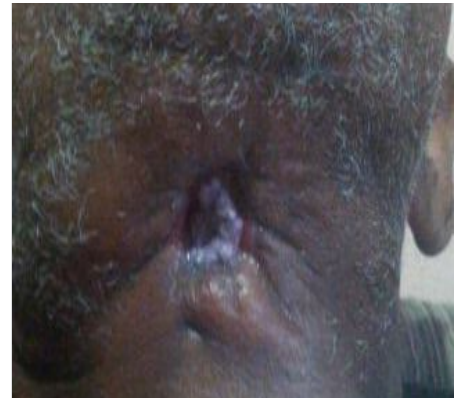



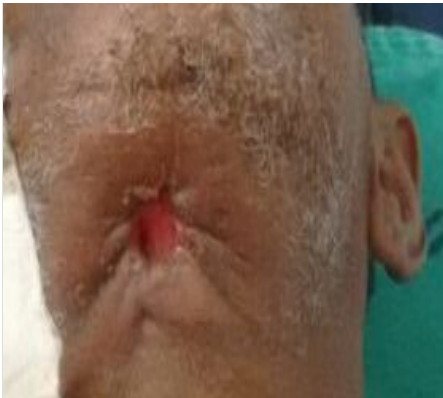Day 1 – Wound with pus before debridement



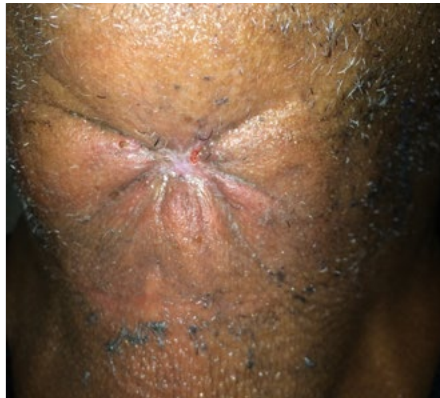Day 4 – Wound size reduction:  
L=5.0 cm, W=3.0 cm



Day 7 – Wound size L=1.5 cm, W=1.5 cm



Day 10 – Wound size L=1.2cm, W=1.5 cm

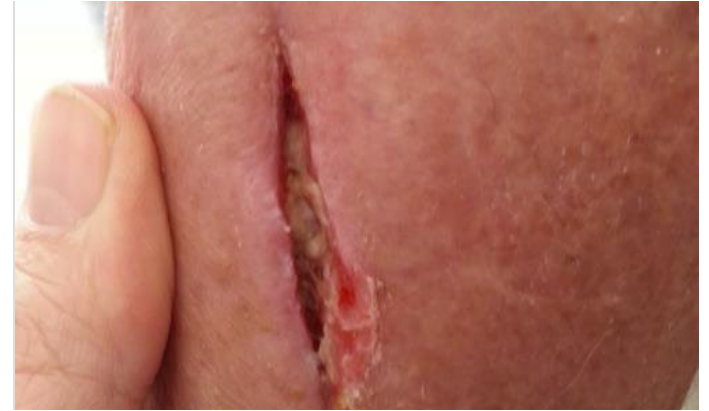
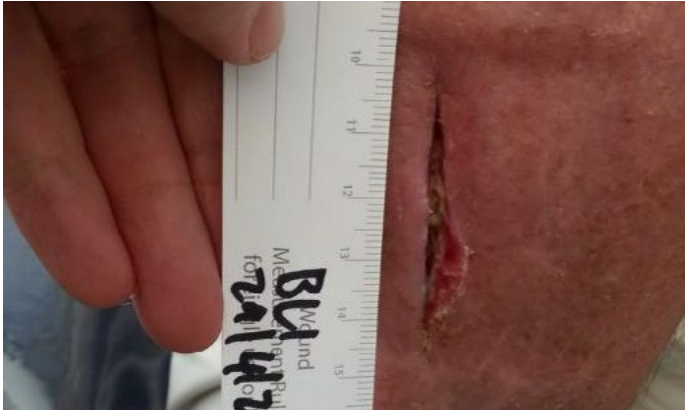
Day 23 – Wound completely healed

# ACUTE WOUNDS

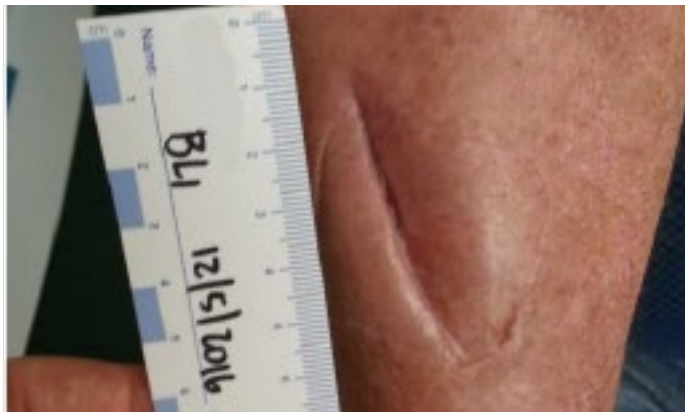
## ASKINA® CALGITROL® PASTE

Responsible practitioner	Liezl Naude, RN
Centre	South Africa
Gender, age (years)	Male, 74 years
Past medical history	-
Wound diagnosis	<ul style="list-style-type: none"><li>• Skin puncture with rusty iron wire</li><li>• Developed severe cellulitis and abscess formation</li></ul>
Wound profile	<ul style="list-style-type: none"><li>• Admitted to hospital on the 6th March</li><li>• Wound measurement: L=37 mm, W=10 mm, D=10 mm</li><li>• Wound bed is composed of 80 % slough, 10 % granulation, tissue and 10 % epithelial tissue</li><li>• Treatment with IV antibiotics in hospital</li><li>• After 8 weeks of treatment the wound measured L=37 mm, W=10 mm, D=10 mm</li></ul>
Previous wound management	Negative Pressure Wound Therapy (NWPT) for 21 days started in March
Reason(s) for switch to Askina® Calgitrol® Paste	Infected wound
Treatment regimen	Askina® Calgitrol® Paste
Other treatment(s) used	-
Clinical outcomes	Complete wound healing less than two weeks following initiation of treatment with Askina® Calgitrol® Paste
Treatment benefits	Paste very easy to apply to this sinus wound
Conclusion	Askina® Calgitrol® Paste in conjunction with IV antibiotics encourages rapid healing of an abscess wound with severe cellulitis



Day 1: Wound at inclusion  
Wound size: L=37 mm, W=10 mm, D=10 mm

Day 1: Wound at inclusion  
Wound size: L=37 mm, W=10 mm, D=10 mm

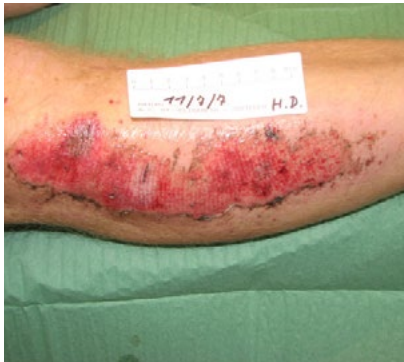

Day 13 – Wound completely healed

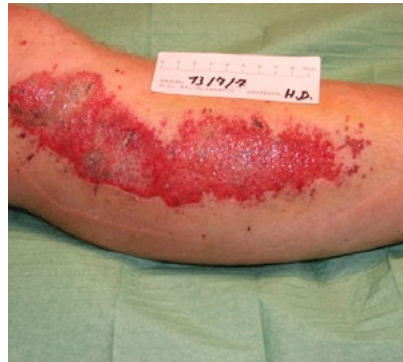# ACUTE WOUNDS

ASKINA® CALGITROL® AG

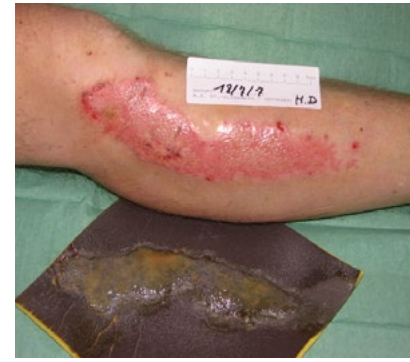Responsible practitioner	Frans Meuleni�re, RN
Centre	AZ St Elisabeth Zottegem, Belgium
Gender, age (years)	-
Past medical history	-
Wound diagnosis	Skin abrasion following fall off from a motorbike
Wound profile	<ul style="list-style-type: none"><li>• Dirty wound on the right arm</li><li>• High level of exudate</li></ul>
Previous wound management	Standard antiseptic treatment
Reason(s) for switch to Askina® Calgitrol® Ag	<ul style="list-style-type: none"><li>• Wound with high risk of infection</li><li>• No improvement after preceding antiseptic treatment</li></ul>
Treatment regimen	<ul style="list-style-type: none"><li>• Wound cleansing with Prontosan® solution</li><li>• Application of Askina® Calgitrol® Ag dressing</li><li>• Dressing changes on average every two days</li></ul>
Other treatment(s) used	-
Clinical outcomes	<ul style="list-style-type: none"><li>• After two days, first dressing removed, appearance of red granulation tissue</li><li>• On Day 20, good evolution in moist wound environment</li><li>• Marked wound improvement by Day 31</li></ul>
Treatment benefits	<ul style="list-style-type: none"><li>• The dressing is easy to use and can be cut to fit the wound size</li><li>• Less frequent dressing changes save nursing time and product cost</li></ul>
Conclusion	Askina Calgitrol® Ag® is a cost effective dressing for the treatment of infected acute wounds



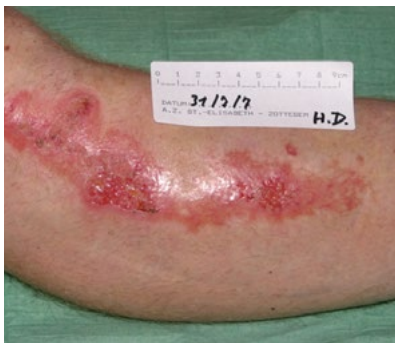Day 1 – Abrasion prior to treatment



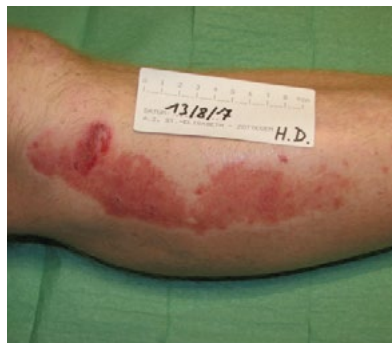Day 2 – First dressing change following treatment with Askina® Calgitrol® Ag



Day 7 – Wound appearance after seven days



Day 20 – Good wound healing process in moist wound environment



Day 31 – Marked wound improvement

## NOTES

This image shows a single sheet of white paper with horizontal blue ruling lines. The lines are evenly spaced and run across the width of the page. There are no margins or other markings on the paper.



Manufactured by: B. Braun Hospicare Lt. | Collooney | Co. Sligo | IRELAND  
[www.bbraun.com/wound-management](http://www.bbraun.com/wound-management)

This document, its contents, including institutional data, information, trademarks and logos mentioned herein are the exclusive property of B. Braun. Any representation and / or reproduction, total or partial, of this document and its contents without the express prior consent of B. Braun, is strictly prohibited and constitutes an infringement of the intellectual property rights of B. Braun.  
Non-binding documents and photographs. For healthcare professional use only.